



#### Özet

Adölesan idiyopatik skolyoz (AİS), ergenlik döneminde oluşan omurganın yapısal olarak yana ve rotasyonel eğilmesi şeklinde görülen en sık pediatrik omurga sorunudur. İskelet matüritesinden önce görülür. Halen sebebi tam olarak bilinmemesi de literatürde AİS doğal seyri iyice ortaya konulmuştur. Konservatif tedavinin ana amacı eğriliğin artmasının önlenmesidir. Breys ve cerrahi günümüzde büyük ve/veya progresif eğrilikler için uygulanmaktadır. Adölesan idiyopatik skolyozda bir çok konservatif tedavi seçeneği mevcuttur. Literatürde bu tedavilerin sonuçlarını özetlemeye çalışan bir çok çalışma olsa da, kabul edilen kullanımları ile ilgili kanıtlar net değildir. Bir çok klinisyen konservatif tedavinin etkinliği konusunda şüphelidir. Bunun nedeni breysin etkinliğinin tanımlanması ve dahil edilme kriterleri konusunda fikir birliği olmamasıdır. SRS (Scoliosis Research Society) çalışmalar arasında doğru ve güvenilir karşılaştırma yapabilmek için gelecekteki tüm AİS breys çalışmalarına yönelik parametreler oluşturdu. Bu kılavuz dahil edilme ve değerlendirme kriterleri önererek ortez çalışmalarını standart hale getirebilir. Böylece farklı breyslerin etkinliğinin daha iyi değerlendirilmesi ve breyslerin faydaları hakkındaki şüphelerin ortadan kaldırılması sağlanabilir. AİS'da ortez tedavisi iskelet matüritesine ulaşıncaya kadar omurga eğriliklerinin kontrolü için kullanılır.

#### Anahtar Sözcükler

Adölesan İdiopatik Skolyoz; İdiopatik Skolyoz

#### Abstract

Adolescent idiopathic scoliosis (AIS), the most common pediatric spine problem, is a structural lateral and rotatory curvature of the spine arising in otherwise normal children during puberty. It occurs before skeletal maturity. Although there is still no cause for AIS, the natural history of AIS has been established in the literature very well. The aim of nonoperative treatment is mainly an attempt to prevent progression of the curve. Bracing and surgery have been used for large and or progressive curves currently. Many conservative treatments are available for adolescents with idiopathic scoliosis (AIS). Although there are numerous studies in literature that have tried to summarize the results of treatment, the evidence for their accepted use is still unclear. Many clinicians skeptical about the efficacy of conservative treatments. Because there is no consistency of both the inclusion criteria and the definitions of brace effectiveness. The definition of success or who should be included in the analysis have never been universally agreed upon. The Scoliosis Research Society established parameters for all future AIS bracing studies to be able to make comparison among studies more valid and reliable. These guidelines may standardize orthotic studies by recommending inclusion and assessment criteria and allow the promotion of the effectiveness of different braces and decrease the suspicion about their usefulness. Orthotic treatment in adolescent idiopathic scoliosis is used to control spinal curvatures while waiting for skeletal maturation.

#### Keywords

Adolescent Idiopathic Scoliosis; Idiopathic Scoliosis

## Introduction

Adolescent idiopathic scoliosis (AIS), the most common pediatric spine problem, is a structural lateral and rotatory curvature of the spine arising in otherwise normal children during puberty [1,2]. It occurs before skeletal maturity. Although there is still no cause for AIS, the natural history of AIS has been established in the literature very well [1-16]. Lonstein and Carlson [2] found that in skeletally immature patients with curves of 20 to 29 degrees, there is a 68% risk of curve progression. They also found that these patients with a curve of  $<20^\circ$  are three times more likely to show curve progression than others. Nachemson and Peterson [17], in a prospective study of 286 girls with curves of  $25^\circ$  to  $35^\circ$ , found the incidence of progression to be 66%. Bunnell [1] reported progression of at least 5 degrees in 68% of patients, 10 degrees in 34% of patients, and 20 degrees in 18% of patients in his series. Rogala et al, [18] also reported significant curve progression in their patients. Long-term follow-ups indicate that patients with scoliosis may have a higher prevalence of back pain, and of significant deformity if the curve becomes extremely large [9,10,16]. Severe thoracic curvatures slightly increase risk for pulmonary dysfunction and corpulmonale [9,10,15]. Large curvatures and large degrees of rotation can cause significant cosmetic deformity and psychologic distress to the patients. The aim of nonoperative treatment is mainly an attempt to prevent progression of the curve. Bracing and surgery have been used for large and or progressive curves currently. Many conservative treatments are available for adolescents with idiopathic scoliosis (AIS).

Although there are numerous studies in literature that have tried to summarize the results of treatment, [11,19-24] the evidence for their accepted use is still unclear [25]. Many clinicians skeptical about the efficacy of conservative treatments [26,27]. Because there is no consistency of both the inclusion criteria and the definitions of brace effectiveness [28]. The definition of success or who should be included in the analysis have never been universally agreed upon. The Scoliosis Research Society (SRS) established parameters for all future AIS bracing studies [28] to be able to make comparison among studies more valid and reliable. These guidelines may standardize orthotic studies by recommending inclusion and assessment criteria [28] and allow the promotion of the effectiveness of different braces and decrease the suspicion about their usefulness. Orthotic treatment in adolescent idiopathic scoliosis is used to control spinal curvatures while waiting for skeletal maturation. Brace treatment attempts to modify mechanically the scoliotic spine shape and control progression of the spinal curvatures by applying specific pressure points on the torso. Most studies have found that curves of  $25^\circ$  to  $45^\circ$  degrees in skeletally immature patients, in whom progression is likely [29] are most suitable for bracing [2,30-32]. But it doesn't reverse the existing curve and is only used for preventing progression. The aim of brace treatment in scoliosis, is to control the lateral spinal curvature and improve the cosmetic appearance of the back.

Although there are some questions about their effectiveness bracing is currently used as a standard nonoperative treatment of AIS [11,27,33-37]. Certain different types of orthoses have been developed for use in patients with AIS [30,31,38-43]. Cervicothoracolumbosacral orthosis or Milwaukee brace, the thoracolumbosacral orthosis (TLSO), and the nighttime orthoses, such as the Providence and the Charleston orthoses have been used with varying degrees of success. Removing of the cervical component, using of lighter materials, and customization of the brace to improve comfort, cosmetics, and

compliance are the recent design developments [44]. Wearing time of braces varies across centers and between braces but most braces are worn for between 16 and 23 hours per day.

Although there are a lot of studies done with these orthoses with variable treatment criteria to show their effectiveness in the treatment of AIS [11,17,20,21,23,30-32,43-56] the effectiveness of orthotic management still remains controversial. The primary purpose of this review is to compare the effectiveness of these orthoses in the treatment of progressive AIS.

## Types of Braces Milwaukee Brace

The most experience is with the Milwaukee orthosis, which is worn 23 hours per day, with relief during bathing and exercise only. A full-time Milwaukee brace, a full torso brace was used for correction and control until a ten years ago. It is still used specifically for high curves. The device consist of a wide flat bar in front and two smaller ones in back. These bars attach to a ring around the neck that has rests for the chin and back of the head. The brace can be periodically adjusted for growth.

Although early reports have indicated that it has the potential to alter the natural history of AIS and prevent curve progression and the need for surgical intervention [2,30,42,51,57-61] subsequent studies with longer follow-up have questioned its effectiveness. These studies showed that after the cessation of brace treatment, curves that had demonstrated some correction at the end of bracing tended then to continually increase toward the pretreatment angle [11,20,22,38,56]. Carr et al [30] reported a 39% surgery rate in patients treated with the Milwaukee orthosis who had long-term follow-up. In skeletally immature patients (Risser sign 0 or 1) with initial curves of 30 to 39 degrees a 47% rate of failure (curve progression of 6 degrees or operative treatment) was reported in Lonstein and Winters study [51]. In the study of Noonan et al, 63% of the 88 patients wearing the Milwaukee brace were classified as a failure. They reported progression in 48% of patients after the brace had been stopped, which necessitated operative fusion in 42% of the series [11].

Compliance is a major problem with this brace. Generally patients does not wear the Milwaukee brace as directed. In addition, the Milwaukee orthosis has been found to have a negative effect on a patients self-image [62]. These problems with Milwaukee orthosis ultimately led to the development of underarm braces, such as the TLSO.

## The Boston and TLSO Braces.

Molded braces called thoracolumbar-sacral orthoses (TLSOs), most often the Boston brace, was developed to prevent curve progression while decreasing the need for a suprastructure, which most patients find cosmetically intolerable [17,31]. TLSO braces which appear to be effective for mid-back and lower curves can be worn beneath the underarms and can be fitted close to the skin so they do not show beneath clothing.

The results of the TLSO were found equivalent to and sometimes superior to those of the Milwaukee orthosis. Although several studies appear to demonstrate good results in patients who wore Boston and Wilmington braces, there are some questions about their sampling, design and measurement issues that could explain these results [21,31,38]. In one study, success rate of 61% which correlated with wearing the brace more than 18 hours a day was reported in patients who wore Boston braces [66]. In a prospective study, Nachemson and Peterson [17] reported a success rate of 74% in controlling curve progression

with the use of a TLSO. In patients who wore Boston braces avoidance of surgery was 88% in the study of Emans et al [31]. Montgomery and Willner [48] mentioned that the Milwaukee orthosis had 5 times greater risk of failure compared with the Boston Brace.

There is a question about the ability of bracing to alter natural history of the AIS. Thirty-six percent of their braced patients had 6° or more of progression compared to 66% in the observation group in the study of Nachemson and Peterson [17]. Seventy-three percent of 120 curves progressed more than 10° despite use of the Boston or Charleston brace in the study of Little et al [63]. Goldberg et al [27] compared surgical rates in a previously untreated cohort (n = 153) with that in a group of braced patients with AIS from 3 previously published studies (Lonstein and Winter, [51] Fernandez-Feliberti et al, [64] and Noonan et al [11]). They haven't found statistically significant difference between them. Spoonamore et al reported 43 (61%) surgery and/or progressed by the time of follow-up in patients who wore the Rosenberger TLSO in preventing curve progression in AIS [65].

Reducing lung capacity by nearly 20%, causing mild, temporary changes in kidney function and being hot are problems with the TLSO braces. High strap forces are necessary to ensure lateral and derotational forces on the spine, but can also cause undesirable forces that induce lordosis.

There is still controversy about the amount of time the brace is worn on a daily basis. Wiley et al [66] found that compliant patients who wore the brace for more than 18 hours per day had less progression than those who wore it 12 hours per day or less.

Emans et al suggested that part-time bracing may be as effective as fulltime bracing and it could be used to decrease psychological morbidity and to improve compliance [31]. In fact both part-time bracing and fulltime bracing have been found to be nearly as effective [31,32,52]. There were no statistical difference in full-time (duration, 23Y24 hours/day) versus part-time (duration, 12Y16 hours/ day) use of the Wilmington brace in the study of Allington and Bowen [52]. Climent and Sanchez [67] found that nighttime-only bracing had the least negative effect on psychological functioning, sleep disturbance, back pain, body image, and flexibility(Figure 1).

### The Charleston Bending Brace

Correction and, sometimes, overcorrection of the deformity with aggressive molding [53,55] have been achieved by using of Charleston and the Providence orthosis. These orthoses which seem to alter the natural history in retrospective studies require 8 to 10 hours of nighttime wear. They had no difference or superiority to the full-time braces in comparison studies [54,56,68].

The Charleston brace is a custom-molded spinal orthosis that reduces the scoliotic curvature by holding the patient in an overcorrected position. The Charleston brace which must be worn for a minimum of 8 hours per night forms an attractive alternative to ambulatory bracing. The patient is casted supine in a bending position opposite the curvature while the orthotist maintains a corrective force at the apex of the curvature. It produces a very good in-brace correction, and no weaning is required before brace discontinuation.

Varying success rates with the use of the Charleston brace have been reported in idiopathic scoliosis [39,53,54,69,70]. Trivedi and Thomson reported 60% success rate in their study [23]. Price et al. [53], in their follow-up report obtained a 66% success rate. Katz et al. [54] compared Boston and Charleston braces and reported a 41% success rate with the Charleston brace as opposed to 61% with the Boston brace in their study. Howard et al. [69] compared Charleston, TLSO, and Milwaukee braces, and found 62% success rate with the Charleston brace. In retrospective study of Katz and Durrani [20] the use of the Boston brace in curves between 36 to 45 degrees was recommended because it prevented curve progression of 6 degrees or more in 57% of patients, as compared with only 17% success in using the Charleston orthosis. The Boston orthosis also prevented progression in 71% of patients which had curves of 25 to 35 degrees versus 53% in using Charleston orthosis. TLSO was superior at preventing curve progression when compared with the Charleston brace (and Milwaukee) in the study of Howard et al [69]. In the study of Gepstein et al [56] there was no statistical difference in the surgery rate of 13,5% using the TLSO and 11% using the Charleston Brace.

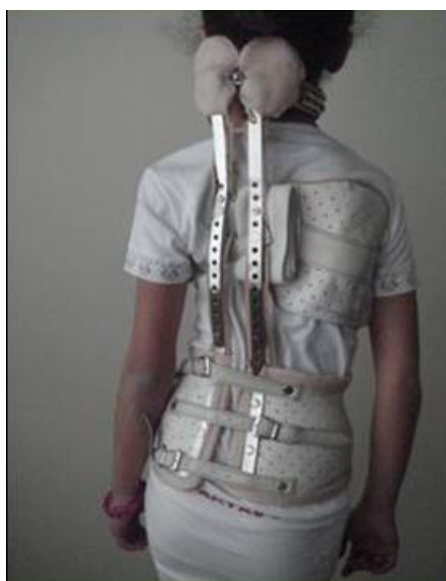

Figure 1. Cervicothoracolumbosacral scoliosis ortesis (Milwakuue brace)

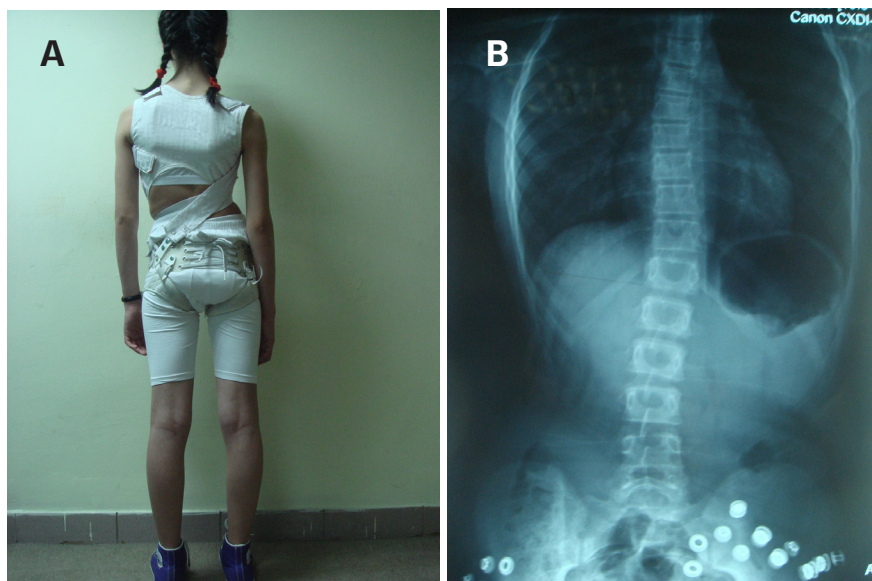


Figure 2. Spinecor brace (A) AP x-ray of 12 years old girl wearing spinecor brace (B)

### The Providence Brace

The Providence brace is a computer-fitted device that is worn only at night. It works by the application of opposing forces and, as opposed to bending the spine, pushes the curve apexes to the midline or past it. It is specifically designed for the individual curvature abnormalities, and early studies are showing promise. D\_Amato et al [55] found excellent correction in the Providence orthosis, with a success rate of 79% if the apex was at or below T9. They stated that the brace was effective in initial curves less than 35 degrees. Janicki et al found that the Providence nighttime orthosis was more effective in avoiding surgery and preventing curve progression than a TLSO in a comparable population of patients with AIS having initial curves of 25 to 40 degrees [71]. It seems that the use of bracing with the TLSO or the Providence brace in curves greater than 35 degrees in the control of AIS is doubtful. Using the Providence orthosis in 25-35 degrees curves seems much more favorable.

### SpineCor

A bracing method called the SpineCor uses adjustable bands and a cotton vest that allows flexibility. The effectiveness of the SpineCor brace has been shown for milder and moderate curves [19]. Coillard et al reported that in patients who had a minimum posttreatment follow-up of 2 years, the brace corrected the curve up to their initial Cobb angle in more than half the patients, while 38% were stabilized and only 7% had curvature that worsened by more than 5 degrees [19]. They also showed that the follow-up of orthopaedic treatment was a success in 95.7% of the patients, with a mean correction angle of 8.6 +/- 1.7 degrees [72]. A recent trial of 24 girls with idiopathic scoliosis compared the SpineCor with a TLSO-type brace. The study indicated that the SpineCor did not halt curvature progression associated with idiopathic scoliosis during the pubertal growth spurt whereas the TLSO device did. A follow-up of 2 years is sufficient to foresee progression after weaning from the brace [73,74]. The SpineCor brace seems to have sustainable correction or stabilization of scoliotic curves up to 2 years after discontinuation of brace treatment. After the end of brace treatment, curves that had showed some correction at the end of bracing with traditional rigid braces tended then to continually increase toward the pretreatment angle in studies with longer follow-up [11,20,22,38]. Noonan et al found 63% failure rate in 88 patients wearing the Milwaukee brace [22]. There was 9 (33%) progression of the curve after a trial of intentional weaning. Wilmington and Boston braces also showed similar loss of correction over time. Gabos et al found an increase in the curvature of 5 degrees or greater between the end of bracing using the Wilmington brace and the time of final follow-up (mean, 14.6 years after the completion of treatment) in 22% of 55 patients [20]. In study of Olafsson et al the mean Cobb angle at treatment start was 32 +/- 6 degrees, 12.1 +/- 7.6 degrees after bracing, 25.4 +/- 11.3 degrees after weaning, and 29 +/- 12 degrees at follow-up in patients with AIS wearing the Boston brace [21]. Coillard et al showed that obtaining a correction or a stabilization of the pretreatment Cobb angle (59.4%), and maintaining the brace success for 2 years after the end of the treatment using SpineCor brace is possible [72]. Maintaining good results up to 2 years of follow-up beyond skeletal maturity makes SpineCor brace very different to the already published literature on brace, in which apparent correction obtained during treatment can be expected to be

lost over time [4,18]. Future studies should be done to support and reinforce this finding. (Figure 2a-b).Dolan and Weinstein abstracted data on surgical rates after observation and bracing from 18 studies. The pooled surgical rate was 23% after bracing and 22% after observation in their review. Comparing the pooled rates for observation and bracing showed no clear advantage of either approach.

All these studies which related to using braces show that there are no exact similarity in terms of curve magnitude, age, brace termination, follow up, data collection in these studies. These results support the need for a larger, multicenter randomized study using the new SRS inclusion and assessment criteria. These studies will be able to determine if these or other new braces provide any additional value. We must overcome these problems and also to ensure that patients are aware of the success and failure rates, the specific risk factors associated with brace failure, and are given the information necessary to make an informed decision concerning brace treatment.

Forthcoming studies using the same standardized criteria for AIS brace studies as described in new SRS inclusion and assessment criteria will allow valid and reliable comparison among braces.

### References

- Bunnell WP. A study of the natural history of idiopathic scoliosis before skeletal maturity. *Spine* 1986;11:773-776.
- Lonstein JE, Carlson JM. The prediction of curve progression in untreated idiopathic scoliosis during growth. *J Bone Joint Surg Am* 1984;66:1061-71.
- Ascani E, Bartolozzi P, Logroscino CA, et al. Natural history of untreated idiopathic scoliosis after skeletal maturity. Symposium on Epidemiology, Natural History and Non-operative Treatment of Idiopathic Scoliosis. *Spine* 1986;11:784-9.
- Bjure J, Nachemson A. Non-treated scoliosis. *Clin Orthop* 1973;93:44-52.
- Bunnell WP. The natural history of idiopathic scoliosis. *Clin Orthop* 1988;229:20-5.
- Collis DK, Ponseti IV. Long-term follow-up of patients with idiopathic scoliosis not treated surgically. *J Bone Joint Surg Am* 1969;51:425-45.
- Fowles JV, Drummond DS, L'Ecuyer S, et al. Untreated scoliosis in the adult. *Clin Orthop* 1978;212-7.
- Lonstein JE. Natural history and school screening for scoliosis. *Orthop Clin North Am* 1988;19:227-37.
- Nachemson A. A long-term follow-up study of non-treated scoliosis. *Acta Orthop Scand* 1968;39:466-76.
- Nilsson U, Lundgren KD. Long-term prognosis in idiopathic scoliosis. *Acta Orthop Scand* 1968;39:456-65.
- Noonan KJ, Weinstein SL, Jacobson WC, et al. Use of the Milwaukee brace for progressive idiopathic scoliosis. *J Bone Joint Surg Am* 1996;78:557-67.
- Picault C, deMauroy JC, Mouilleseaux B, et al. Natural history of idiopathic scoliosis in girls and boys. *Spine* 1981;11:777-8.
- Weinstein SL. Natural history of curve progression. Symposium on Epidemiology, Natural History and Non-operative Treatment of Idiopathic Scoliosis. *Spine* 1986;11:780-3.
- Weinstein SL, Ponseti IV. Curve progression in idiopathic scoliosis. *J Bone Joint Surg Am* 1983;65A:447-55.
- Weinstein SL, Zavala DC, Ponseti IV. Idiopathic scoliosis: long-term follow-up and prognosis in untreated patients. *J Bone Joint Surg Am* 1981;63A:702-12.
- Weinstein SL, Dolan LA, Spratt K, et al. Health and function of patients with untreated idiopathic scoliosis: a 50-year natural history study. *JAMA* 2003;289:559-67.
- Nachemson AL, Peterson L-E. Effectiveness of treatment with a brace in girls who have adolescent idiopathic scoliosis. *J Bone Joint Surg Am* 1995;77:815-22.
- Rogala EJ, Drummond DS, Gurr J. Scoliosis: Incidence and natural history. A prospective epidemiological study. *J Bone Joint Surg Am* 1978;60:173-6.
- Coillard C, Leroux MA, Zabjek KF, et al. SpineCorVa non-rigid brace for the treatment of idiopathic scoliosis: post-treatment results. *Eur Spine J*. 2003;12:141-148.
- Katz DE, Durrani AA. Factors that influence outcome in bracing large curves in patients with adolescent idiopathic scoliosis. *Spine*. 2001;26:2354-2361.
- Olafsson Y, Saraste H, Soderlund V, et al. Boston brace in the treatment of idiopathic scoliosis. *J Pediatr Orthop*. 1995;15:524-527.
- Gabos PG, Bojeskul JA, Bowen JR, et al. Long-term follow-up of female patients with idiopathic scoliosis treated with the Wilmington orthosis. *J Bone Joint Surg Am*. 2004;86-A:1891-1899.
- Trivedi JM, Thomson JD. Results of Charleston bracing in skeletally immature patients with idiopathic scoliosis. *J Pediatr Orthop*. 2001;21:277-280.
- Spoonamore MJ, Dolan LA, Weinstein SL. Use of the Rosenberger brace in the treatment of progressive adolescent idiopathic scoliosis. *Spine*. 2004;29:1458-

1464.

25. Lenssinck ML, Frijlink AC, Berger MY, et al. Effect of bracing and other conservative interventions in the treatment of idiopathic scoliosis in adolescents: a systematic review of clinical trials. *Phys Ther.* 2005; 85:1329-1339.
26. Goldberg CJ, Dowling FE, Hall JE, et al. A statistical comparison between natural history of idiopathic scoliosis and brace treatment in skeletally immature adolescent girls. *Spine.* 1993;18:902-908.
27. Goldberg CJ, Moore DP, Fogarty EE, et al. Adolescent idiopathic scoliosis: the effect of brace treatment on the incidence of surgery. *Spine.* 2001;26:42-47.
28. Richards BS, Bernstein RM, D\_Amato CR, et al. Standardization of criteria for adolescent idiopathic scoliosis brace studies: SRS Committee on Bracing and Nonoperative Management. *Spine.* 2005;30: 2068-2075.
29. Noonan KJ. Nonsurgical techniques in adolescent idiopathic scoliosis. In: Weinstein SL, ed. *The Pediatric Spine: Principles and Practice.* 2nd ed. Philadelphia, PA: Lippincott, Williams and Wilkins; 2001. p 478-489
30. Carr WA, Moe JH, Winter RB, et al. Treatment of idiopathic scoliosis in the Milwaukee brace. *J Bone Joint Surg Am* 1980;62: 599-612.
31. Emans JB, Kaelin A, Bancel P, et al. The Boston bracing system for idiopathic scoliosis: a follow-up results in 295 patients. *Spine* 1986;11:792-801.
32. Green NE. Part-time bracing of adolescent idiopathic scoliosis. *J Bone Joint Surg Am* 1986;68:738-42.
33. Bunnell WP, MacEwen GD, Jayakumar S. The use of plastic jackets in the non-operative treatment of idiopathic scoliosis. *J Bone Joint Surg Am* 1980;62A:31-8.
34. Dickson RA. Conservative treatment for idiopathic scoliosis. *J Bone Joint Surg Br* 1985;67:176-81.
35. Dickson RA, Weinstein SL. Bracing (and screening)—yes or no? *J Bone Joint Surg Br* 1999;81:193-8.
36. Goldberg CJ, Fogarty EE, Moore DP, et al. Scoliosis and developmental theory: adolescent idiopathic scoliosis. *Spine* 1997;22:2228-37; Discussion 37-8.
37. Miller JA, Nachemson AL, Schultz AB. Effectiveness of braces in mild idiopathic scoliosis. *Spine* 1984;9:632-5.
38. Bassett G, Bunnell W, MacEwen G. Treatment of idiopathic scoliosis with the Wilmington brace. Results in patients with a twenty to thirty-nine degree curve. *J Bone Joint Surg Am* 1986;68A:602-5.
39. Federico DJ, Renshaw TS. Results of treatment of idiopathic scoliosis with the Charleston bending orthosis. *Spine* 1990;15:886-7.
40. Price CT, Scott DS, Reed FE Jr, et al. Nighttime bracing for adolescent idiopathic scoliosis with the Charleston bending brace. Preliminary report. *Spine* 1990;15:1294-9.
41. McCollough NC 3rd, Schultz M, Javech N, et al. Miami TLSO in the management of scoliosis: preliminary results in 100 cases. *J Pediatr Orthop* 1981;1:141-52.
42. Andriacchi T, Schultz A, Belytschko T, et al. Milwaukee brace correction of idiopathic scoliosis. *J Bone Joint Surg Am* 1976;58A:806-15.
43. Moe JH, Kettleson DN. Idiopathic scoliosis. Analysis of curve patterns and the preliminary results of Milwaukee-brace treatment in one hundred sixty-nine patients. *J Bone Joint Surg Am* 1970;52:1509-33.
44. Weinstein SL. Advances in the diagnosis and management of adolescent idiopathic scoliosis. *J Pediatr Orthop* 1994;14:561-3.
45. Mellencamp D, Blount W, Anderson A. Milwaukee brace treatment of idiopathic scoliosis: late results. *Corr Farm.* 1977;126:47-57.
46. Hanks GA, Zimmer B, Nogi J. TLSO treatment of idiopathic scoliosis. An analysis of the Wilmington brace. *Spine.* 1988;13:626-629.
47. Peltonen J, Poussa M, Ylikoski M. Three-year results of bracing in scoliosis. *Acta Orthop Scand.* 1988;59:487-490.
48. Montgomery F, Willner S. Prognosis of brace treated scoliosis. Comparison of Boston and Milwaukee methods in 244 girls. *Acta Orthop Scand.* 1989;60:383-385.
49. Piazza MR, Bassett GS. Curve progression after treatment with the Wilmington brace for idiopathic scoliosis. *J Pediatr Orthop.* 1990; 10:39-43.
50. Willers U, Normelli H, Aaron S, et al. Long-term results of Boston brace on vertebral rotation in AIS. *Spine.* 1993;18:432-435.
51. Lonstein JE, Winter RB. The Milwaukee brace for the treatment of adolescent idiopathic scoliosis. A review of 1020 patients. *J Bone Joint Surg Am.* 1994;76:1207-1221.
52. Allington NJ, Bowen JR. Adolescent idiopathic scoliosis: treatment with the Wilmington brace. A comparison of full-time and part-time use. *J Bone Joint Surg Am.* 1996;78:1056-1062.
53. Price CT, Scott DS, Reed FR, et al. Nighttime bracing for adolescent idiopathic scoliosis with the Charleston bending brace: long-term follow-up. *J Pediatr Orthop.* 1997;17:703-707.
54. Katz DE, Richards BS, Browne RH, et al. A comparison between the Boston brace and the Charleston bending brace in adolescent idiopathic scoliosis. *Spine.* 1997;22:1302-1312.
55. D\_Amato CR, Griggs S, McCoy B. Nighttime bracing with the Providence brace in adolescent girls with idiopathic scoliosis. *Spine.* 2001;26:2006-2012.
56. Gepstein R, Leitner Y, Zohar E, et al. Effectiveness of the Charleston bending brace in the treatment of single-curve idiopathic scoliosis. *J Pediatr Orthop.* 2002;22:84-87
57. Cochran T, Nachemson A. Long-term anatomic and functional changes in patients with adolescent idiopathic scoliosis treated with the Milwaukee brace. *Spine* 1985;10:127-33.
58. Edmonsson AS, Morris JT. Follow-up study of Milwaukee brace treatment in patients with idiopathic scoliosis. *Clin Orthop* 1977;58-61.
59. Keiser RP, Shufflebarger H. The Milwaukee brace in idiopathic scoliosis. Evaluation of 123 completed cases. *Clin Orthop* 1976;118:19-24.
60. Mellencamp DD, Blount WP, Anderson AJ. Milwaukee brace treatment of idiopathic scoliosis: late results. *Clin Orthop* 1977;47-57.
61. Salanova D. Late results of the Milwaukee brace. *Orthop Trans* 1986;10:2.
62. Clayson D, Luz-Alterman S, Cataletto MM, et al. Long-term psychological sequelae of surgically versus nonsurgically treated scoliosis. *Spine.* 1987;12:983-986.
63. Little DG, Song KM, Katz D, et al. Relationship of peak height velocity to other maturity indicators in idiopathic scoliosis in girls. *J Bone Joint Surg Am* 2000;82:685-93.
64. Fernandez-Feliberti R, Flynn J, Ramirez N, et al. Effectiveness of TLSO bracing in the conservative treatment of idiopathic scoliosis. *J Pediatr Orthop* 1995;15:176-81.
65. Spoonamore MJ, Dolan LA, Weinstein SL. Use of the Rosenberger brace in the treatment of progressive idiopathic adolescent scoliosis. *Spine* 2004;29(13):1458-1464.
66. Wiley JW, Thomson JD, Mitchell TM, et al. Effectiveness of the Boston brace in treatment of large curves in adolescent idiopathic scoliosis. *Spine.* 2000;25:2326-2332.
67. Climent JM, Sanchez J. Impact of the type of brace on the quality of life of adolescents with spine deformities. *Spine.* 1999;24:1903-1908.
68. Karol LA. Effectiveness of bracing in male patients with idiopathic scoliosis. *Spine.* 2001;26:2001-2005.
69. Howard A, Wright JG, Hedden D. A comparative study of TLSO, Charleston, and Milwaukee braces for idiopathic scoliosis. *Spine* 1998;22:2401-11.
70. Price CT, Scott DS, Reed FE, et al. Nighttime bracing for adolescent idiopathic scoliosis with the Charleston bending brace: preliminary report. *Spine* 1990;15:1294-9.
71. Janicki JA, Poe-Kochert C, Armstrong DG, Thompson GH. A Comparison of the Thoracolumbosacral Orthoses and Providence Orthosis in the Treatment of Adolescent Idiopathic Scoliosis Results Using the New SRS Inclusion and Assessment Criteria for Bracing Studies. *J Pediatr Orthop* 2007;27:369-374.
72. Coillard C, Vachon V, Circo AB, Beausejour M, Rivard CH. Effectiveness of the SpineCor Brace Based on the New Standardized Criteria Proposed by the Scoliosis Research Society for Adolescent Idiopathic Scoliosis *J Pediatr Orthop* 2007;27:375-379.
73. Montgomery F, Willner S, Appelgren G. Long-term follow-up of patients with adolescent idiopathic scoliosis treated conservatively: an analysis of the clinical value of progression. *J Pediatr Orthop.* 1990;10:48-52.
74. Dolan LA, Weinstein SL. Surgical Rates After Observation and Bracing for Adolescent Idiopathic Scoliosis An Evidence-Based Review. *Spine* 2007;32:91-100.